

Anatomical Studies on the Colon of Female Albino Rats at Different Ages

¹Korzerzer, Rachel Mngu-suur
& ²Shinbo, Jacob
^{1&2}Federal University of Agriculture,
Makurdi, Nigeria

Abstract

The characteristics of anatomically healthy colon are an important element in describing the pathological processes of the colon with age. Fifteen female albino rats at two, four and six months of age were obtained from the Benue state University, Makurdi, Nigeria. The animals were placed into three groups of 5 rats each as Group A, B and C for two months, four months and six months old respectively. All groups were acclimatized for fourteen days, during which periods were fed pelletised grower feed (Vital feeds) and water ad libitum. After 14 days of acclimatization, the animals were sacrificed by intravenous injection of 40mg/kg of thiopental sodium, then a thoraco-lumbar incision was made to expose the digestive tract and the colon dissected out for anatomical studies. Grossly, the weight and length of colon increased as body-weight of the animals increased with age. Histological studies showed that the colon epithelium is simple columnar with numerous crypts and absence of villi. Also, at histology, it was observed that the crypt height and width also increased with age. One interesting observation was the presence of colon fission in the six months old group, which suggested that colon fission increased dramatically with age, which could also suggest that as an animal ages, the cells of the rate at which the colonic cells replicate increases. In conclusion, this study was able to show that the rate of colon growth was more pronounced at six months old albino rat due to the presence of intense colon fission. From this study, it is established that age could be a predisposing factor to colon cancer.

Keywords: *Colon, Anatomy, Histology, Age*

Corresponding Author: Korzerzer, Rachel Mngu-suur

Background to the Study

Aging is a biological process that occurs in all living organisms (Kennedy, Berger, Brunet, Campisi, Cuervo, Epel, Franceschi, Lithgow, Morimoto, Pessin, Rando, Richardson, Schadt, Wyss-Coray and Sierra, 2014). It is manifested by a gradual decline of normal anatomy and physiological functions in a time-dependent manner (Kennedy, Berger, Brunet, Campisi, Cuervo, Epel, Franceschi, Lithgow, Morimoto, Pessin, Rando, Richardson, Schadt, Wyss-Coray, and Sierra, 2014).

Aging holds significant importance for animal and human health because it increases susceptibility to many diseases, including metabolic disorders such as diabetes, cardiovascular disorders, neurodegenerative diseases and cancer (Brunet and Berger, 2014). Aging is characterized by degeneration of essential functions in the post reproductive phase with a decline in functions and decrease in the ability of the body to maintain homeostasis (Salmon, Richardson & Pérez, 2010). The rate of aging is species-specific, indicating that aging has a strong genetic component (Salmon, Richardson and Pérez, 2010).

In the gastrointestinal tract, disorders such as an increased incidence of motility and transit related problems (Salmon, Richardson & Pérez, 2010) are frequently common with age. The morphological and biochemical changes that occurs in human intestinal mucosa under different physiological and pathological conditions have been studied using the rat as a model (Nikki, Anthony & Robert 2005). However, some structural changes can only be detected using morphometric procedures. In the albino rat, the histology of duodenum was studied but no data on the anatomy of the colon and hence the basis for this study. The intestine undergoes a series of adaptive changes during postnatal development, similar to other organs. In the intestinal mucosa, these changes occur largely in structures related to the exchange and absorption processes, such as villi, crypts, enterocytes and microvilli.

Statement of Problem

Intestinal pathologies, especially of the colon are very common (Fodde, 2002). Colorectal cancers are one of the leading causes of cancer related deaths worldwide. Although transgenic mice are commonly used in intestinal cancer research, data regarding the anatomy of healthy intestinal mucosa in mice are still scanty. The existing morphological studies of the intestine of rodents are limited only to assessment of the tumours that occur (Fodde, 2002).

The characteristics of anatomically healthy colon would be an important element in describing the pathological processes of the colon. Moreover, the prevention of cancer is mainly directed to the normal tissue in order to protect it from the development of a lesion. In view of this, the present research was designed to describe the anatomical characteristics of the albino rat colon.

Objectives of the Study

The main objective of the study aims to examine the following:

1. To conduct anatomical studies on the colon of the albino rat at different age groups
2. To conduct a histology of the colon of female albino rat at two, four and six months of age

Justification of the Research

Laboratory animals are suitable subjects for many modern experimental and biomedical research including metabolic studies, tumor and cancer investigation, anatomical, and biochemical research, and experimental transplantation. Currently, the laboratory mammals are also used as animal models for both veterinary and human research. The knowledge of anatomical variations among species is important for experimental investigation and surgical practice. The investigation of anatomy, comprising the morphology and histology of the colon in albino rat is needed in-order to detect an altered structure.

Morphological changes of the intestine have more often been used in the assessment of intestinal pathology (Walthall, Cappon, Hurtt and Zoetis, 2005). The colon plays a major role in both digestion and absorption processes of various complex carbohydrates and, to a lesser extent, proteins that prove resistant to digestion and absorption in the more proximal intestine (Rombeau, 2003). Unlike the small intestine, the colon salvages nutrients from these products via fermentation. Fermentation occurs by means of the saccharolytic and proteolytic members of the over 400 species of bacteria, the majority of which are obligate anaerobes, present within the colon (Nordgaard, 1998). Approximately 10% of ingested carbohydrates enter the caecum as undigested material (Bharucha and Camilleri, 2007). This research could be used as a model for comparative experimental research using the albino rat as a model for human problems such as cancer of the colon, diagnosis and assessment of intestinal pathology and in studies of intestinal development, the morphological and biochemical changes that occur largely in structures related to the exchange and absorption processes.

Materials and Methods

Animal Source

Fifteen (15) apparently healthy female albino rats, aged two, four and six months of age were purchased from the College of Health Sciences, Benue state University, Makurdi, and transported by means of constructed cages to the research laboratory of the Department of Veterinary Anatomy, Federal University of Agriculture, Makurdi. Ethical clearance was sought and obtained from the ethical committee on animal use, Faculty of Veterinary Medicine, Ahmadu Bello University, Zaria.

Experimental Design

The animals were divided into three groups of five animals in each group as group A, B and C according to their ages as two, four and six months respectively and acclimatized for 14 days. During period of acclimatization, animals were fed pelletised grower and tap water ad libitum. The animals were cared for and treated in accordance with the guidelines for laboratory animals established by the National Institute of Health as well as those laid down by the local ethical committee. Ethical clearance was obtained for this study. Animals were weighed prior to acclimatization and after acclimatization, after which termination was done by 40mg/kg thiopental sodium. A thoraco-lumbar incision was done to expose the digestive tract, identify and transect the colon for routine histology.

Histological Technique

The portion of the descending colon was labelled and fixed for 48 hours in 10% neutral buffered formalin. Dehydration was done through a series of graded alcohol (70%, 80%, 90%, 95% and 100%). This was then cleared with xylene and infiltrated with molten paraffin wax. Sections of

5 μ thick were made from the embedded tissues using a microtome, both the longitudinal and cross sections were obtained. The sections were then mounted on grease free glass slides and stained with Haematoxylin and Eosin (H&E) stain for routine histological studies. The slides were examined using a light microscope Olympus, CHB made in Tokyo Japan. All variables were studied at X40, X100 and X250 magnifications. Photographs of the tissues were taken using AmScope MT series Microscope Camera connected to a computer.

Statistical Analysis

Levene's test of homogeneity of variance was conducted to evaluate the assumption of equality of variances (Colon weight and length, body weight and length). Post-hoc comparisons using Tukey's HSD test were conducted. The one-way analysis of variance was done to ascertain the significance of colon length and weight with age and crypt height and width with age.

Results

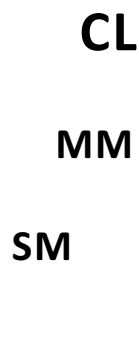
Gross Observations

The colon of albino rat was observed to be attached to the caecum proximally. The most cranial segment was identified as the ascending colon which ran towards the thoracic cavity extending from the left to right sides to form the transverse colon, and then the descending colon which ran from the side of the liver downwards to the rectum.

Histological Studies

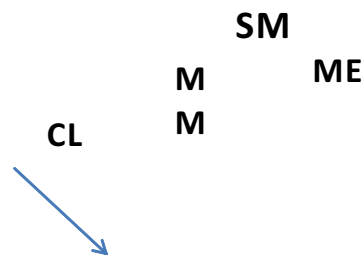

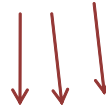Figure 1. Photomicrograph of Colon of two months old albino rat showing Crypt of Lieberkuhn (CL). Note the absence of crypt fission. Muscularis mucosa (MM), submucosa (SM) and muscularis externa (ME). Arrows show the simple columnar epithelium of the Crypts. H & E X250.



Picture 2. Photomicrograph of Colon of four months old albino rat showing Crypts of Lieberkuhn (CL), note the absence of crypt fission here, Muscularis externa (ME), submucosa (SM), and Muscularis mucosa (MM). H & E X250

MALT



Gb

CL

Figure 3.Photomicrograph of Colon of six months old albino rat showing Goblet cells (Gb), Mucosa associated lymphoid tissue (MALT) and the crypts of Lieberkuhn (CL). Note the division within the crypts shown by the arrows (Fission). H&E X250.

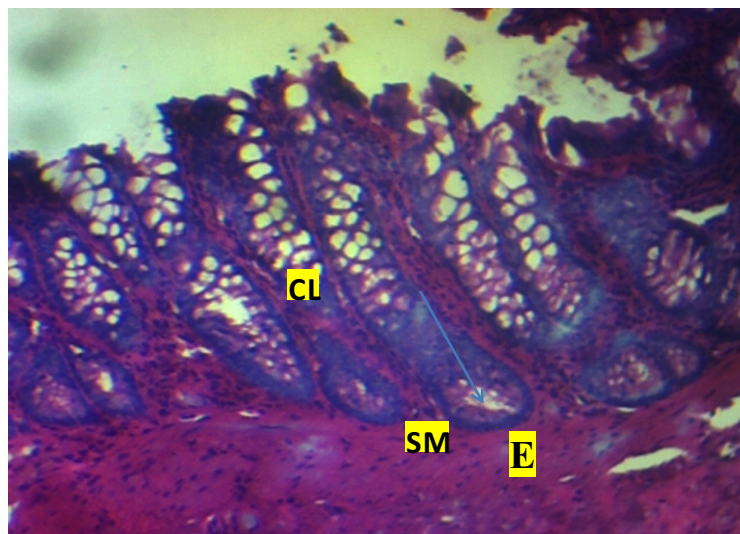


Figure 4.Photomicrograph of Colon of six months old albino rat showing intense colonic fission, almost all the crypts show division, submucosa (SM) and Epithelium (E) shown by the arrow. H&E X250.

Discussion

In this study, histology of the colon revealed the epithelium to be simple columnar with goblet cells, and this is thought to be responsible for the regulation of movement of electrolyte and water in and out of the colonic mucosa.

Crypt fission was seen in the six months old group of albino rats, which suggests that crypt fission is required in the production of more crypts as an animal advances in age (Totafurno, J., Bjerknes, M. and Cheng, H. et al., 1987).

The colonic crypts are the sites where mutations affecting the stem cells can occur leading to the emergence and progression of colorectal cancer. These mutations could manifest as a rapid increase in colonic fission beyond normal index.

In conclusion, it is observed from this study that there exists a relationship between age and proliferation of the colon. Proliferation of the colon occurs through a process known as crypt

fission, and this could predispose to cancer. By this understanding, ways of regulating crypt fission can be devised as an animal advances in age as a preventive measure to colon cancer. It is recommended that aging animals feed healthy diet to protect the colon from abnormal cell divisions.

References

- Brunet, A. & Berger, S. L. (2014). Epigenetics of aging and aging-related disease. *Journal of Gerontology a Biol. Sci. Med. Sci.*, 69
- Fodde, R. (2002). The APC gene in colorectal cancer. *European Journal of Cancer*, 38: 867–871.
- Finch, C. E. (1990). *Longevity, Senescence, and the Genome*. London: The University of Chicago Press, Chicago
- Gregorieff, A. & Clevers, H. (2005). Wnt signaling in the intestinal epithelium: from endoderm to cancer. *Genes Development*, 19: 877–890
- Hyun-Sook, P., Robert, A.G. & Nicholas, A.W. (1995). Crypt fission in the small intestine and colon. *American Journal of Pathology*, 147: 1416-1428
- Kennedy, B. K., Berger, S. L., Brunet, A., Campisi, J., Cuervo, A. M., Epel, E. S., Franceschi, Lithgow, C., G. J., Morimoto, R. I., Pessin, J. E., Rando, T. A., Richardson, A., Schadt, E., Wyss-Coray, E., T. & Sierra, F. (2014). Geroscience: Linking aging to chronic disease. *Cell*, 159: 709–713
- Mural, R.J., Adams, M.D., Myers, E.W., Smith, H.O., Miklos, G. L., Wides, R. & Halpern, A. (2002). A comparison of whole-genome shotgun-derived mouse chromosome 16 and the human genome. *Science*, 296: 1661–1671
- Nikki, M., Anthony, J. F. & Robert, A.G. (2005). Differences in the effects of age on the intestinal proliferation, crypt fission and apoptosis on the small intestine and the colon of rat. *International Journal of Experimental Pathology*, 86(2): 125-130
- Nordgaard, I. (1998). Colon as a digestive organ: the importance of colonic support for energy absorption as small bowel failure proceeds. *Dan Medical Bulletin*, 45: 135–56
- Rachmilewitz, D., Simon, P.L., West, G.A., & Cominelli, F. (1993). Localisation of intestinal interleukin 1 gas activity and protein and gene expression to lamina propria cells. *Gastroenterology*, 104(3): 749-758
- Rattan, S.I. (1995). Gerontogenes: real or virtual? *Faseb Journal*, 9: 284–286
- Rombeau, J.L. (2003). *Rethinking the human colon: a dynamic metabolic organ*. Contemporary Surgery, 59: 450–452
- Salmon, A.B., Richardson, A. & Pérez, V.I. (2010). *Update on the oxidative stress theory of aging: does oxidative stress play a role in aging or healthy aging?* Free Radical Biology and Medicine, 48: 642-655

- Saudi, W.S.W., Khan, J. & Islam, M.N. (2009). Small intestinal morphology and permeability in chronic water avoidance stress in rats. *International Morphology Journal*, 16(2), 87-91
- Suzuki, T. & Hara, H. (2010). Dietary fat and bile juice, but not obesity, are responsible for the increase in small intestinal permeability induced through the suppression of tight junction protein expression in LETO and OLETF rats. *London: Nutrition and Metabolism* 12: 7-19
- Totafurno, J., Bjerknes, M. & Cheng, H. (1987). The crypt cycle. Crypt and villus production in the adult intestinal epithelium. *Biophysiology Journal*, 52:279-94
- Walthall, K., Cappon, G.D., Hurtt, M. E. & Zoetis, T. (2005). Postnatal development of the gastrointestinal system: A species comparison. *Birth Defects Resource (Part B)*, 74: 132-156